

## American College of Veterinary Dermatology Mock Exam (2022)

The intent of this mock exam is to familiarize ACVD board exam candidates with the nature and style of questions that may be asked on the ACVD board-certifying exam. ACVD board exam candidates are referred to the “ACVD Program and Study Guide” for an accurate and up-to-date breakdown of species- and knowledge domain-specific questions that can be expected on the ACVD board-certifying exam.

**Number of Questions:** 15

**Total Exam Points:** 15.00

### Question #1:

A two-year-old castrated male domestic shorthaired cat is presented to a veterinary dermatologist for erythematous and crusted plaques on the concave pinnae that extend into the external ear canals. Skin biopsies are collected and submitted for routine histology. The biopsy report describes “severe epidermal hyperplasia and parakeratotic hyperkeratosis that extend into the follicular infundibula” as well as “apoptotic keratinocytes with satellitosis within the outer root sheath”. These findings are most consistent with a diagnosis of:

- A. Pemphigus foliaceus
- B. Erythema multiforme
- C. Proliferative and necrotizing otitis externa
- D. Thymoma-associated exfoliative dermatitis

### Question #2:

What is the mechanism of action of rifampicin’s antimicrobial activity?

- A. Inhibition of DNA gyrase
- B. Inhibition of folic acid synthesis
- C. Inhibition of the 50S ribosomal subunit
- D. Inhibition of DNA-dependent RNA polymerase

### Question #3:

Cross-reactive carbohydrate determinants can result in false positive test results for which group of allergens when performing allergen-specific IgE serology?

- A. Mites
- B. Molds
- C. Pollens
- D. Danders

**Question #4:**

A twenty-year-old American Quarter Horse gelding is presented to a veterinary dermatologist for evaluation of mild to moderate pruritus. On dermatologic exam, the horse is noted to be in poor body condition with moderate diffuse scaling. The following organism is detected on acetate tape impressions from the affected skin. What is the identity of this organism?



- A. *Chorioptes equi*
- B. *Werneckiella equi*
- C. *Haematopinus asini*
- D. *Trombicula alfreddugesi*

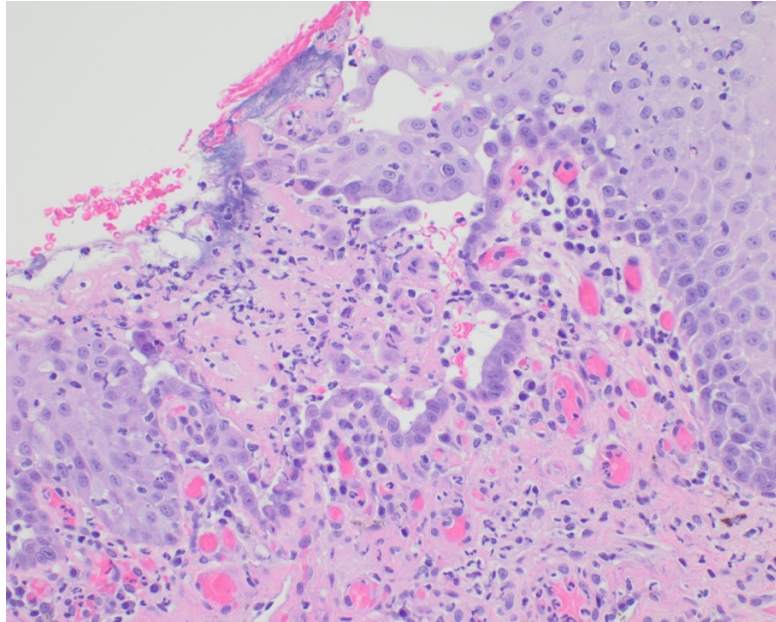
**Question #5:**

A four-month-old in-tact female Golden Retriever is presented to a veterinary dermatologist for moderate scaling along the trunk and mild hyperpigmentation of the ventrum. Skin biopsies are obtained and submitted for routine histology. The biopsy report describes “diffuse lamellar orthokeratotic hyperkeratosis in the absence of epidermal hyperplasia and dermal inflammation”. A mutation in which of the following genes has been found to be associated with this condition?

- A. TGM1
- B. KRT10
- C. NIPAL4
- D. PNPLA1

**Question #6**

An eleven-year-old castrated male Dachshund is presented to a veterinarian for mucocutaneous skin lesions. On dermatologic exam, multifocal to coalescing erosions and ulcers are noted on the nasal planum, tongue, buccal mucosa, gingiva, and hard palate. Skin biopsies are collected and submitted for routine histology. A representative photomicrograph of a hematoxylin and eosin-stained skin section is included below. Which protein is likely targeted by autoantibodies in this dog?



- A. Collagen VII
- B. Laminin-332
- C. Desmoglein-3
- D. Desmocollin-1

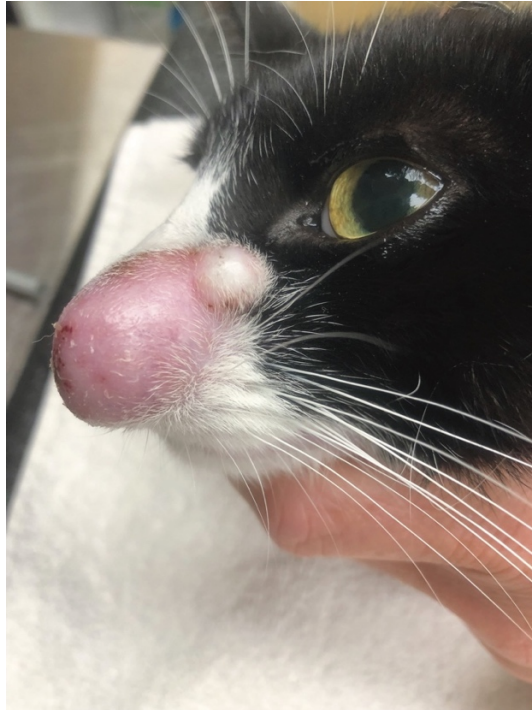**Question #7:**

Which of the following cytokines plays a key role in the development and release of eosinophils from the bone marrow?

- A. IL-4
- B. IL-5
- C. IL-13
- D. IL-31

**Question #8:**

A two-year-old castrated male domestic shorthaired cat is presented to a veterinarian for evaluation of the skin lesions shown in the image below. The owner adopted the cat from a dairy farm as a kitten. Based on the history and clinical image, what is the most likely etiologic agent for the depicted skin lesions?



- A. *Microsporium gypseum*
- B. *Mycobacterium fortuitum*
- C. *Felis catus* papillomavirus type 2
- D. *Bos taurus* papillomavirus type 14

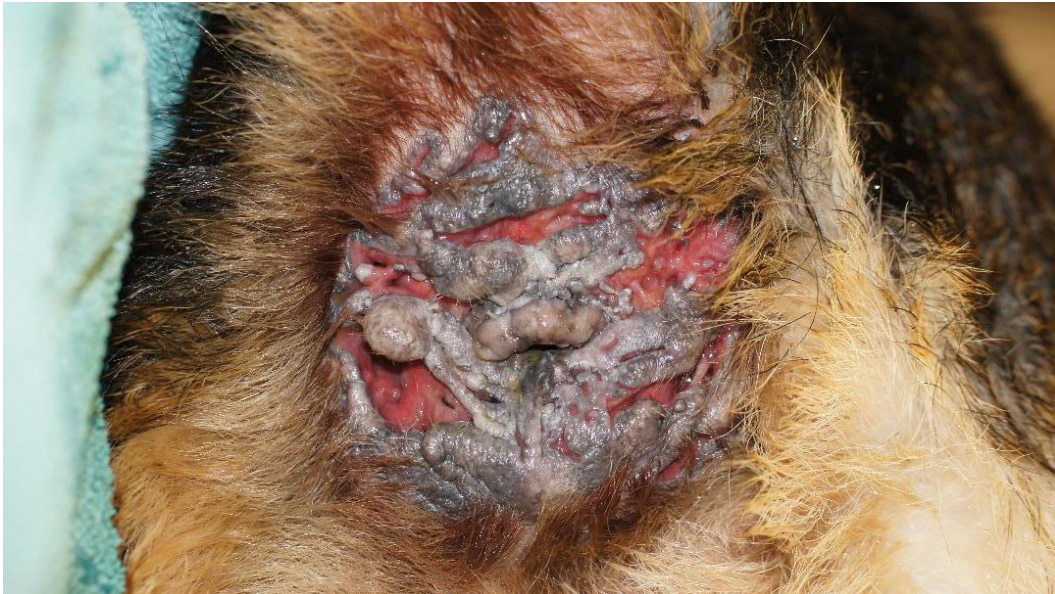**Question #9:**

Methicillin-resistant *Staphylococcus pseudintermedius* are most often resistant to which of the following antibiotics?

- A. Rifampicin
- B. Clindamycin
- C. Vancomycin
- D. Chloramphenicol

**Question #10:**

A four-year-old German Shepherd Dog is presented to a veterinarian for the skin lesions shown in the image below. In addition to the skin lesions, the owner reports intermittent constipation. Based on the history and clinical image, what is the most likely diagnosis?



- A. Anal sacculitis
- B. Anal furunculosis
- C. Chronic atopic dermatitis
- D. Perianal adenocarcinoma

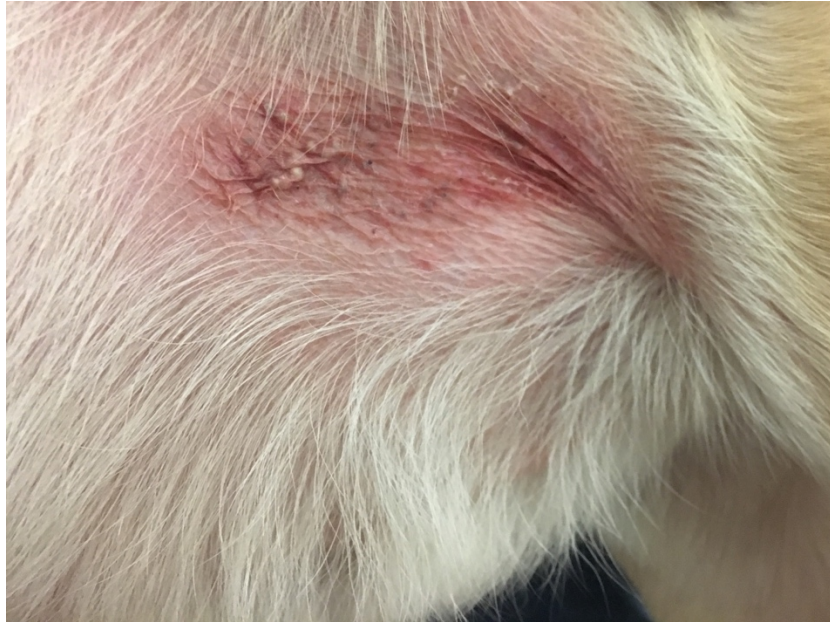**Question #11:**

A ten-month-old in-tact female Portuguese Water Dog is presented to a veterinarian for frequent skin lacerations that develop while playing with other littermates. On dermatologic exam, the skin is noted to be hyperextensible and hanging in loose, pendulous folds. Thin, pale, and wrinkled scars are noted at sites where previous lacerations have healed. Skin biopsies are collected and submitted for routine histology. Which histologic stain can assist in making a tentative diagnosis of the most likely disease process?

- A. Von Kossa
- B. Congo red
- C. Alcian blue
- D. Masson trichrome

**Question #12:**

An eight-year-old castrated male Labrador retriever with a history of non-seasonal canine atopic dermatitis is presented to a veterinary dermatologist for an annual recheck. The owner reports a non-healing “rash” on the ventral abdomen depicted in the image below. What is the appropriate treatment recommendation for the skin lesions depicted in the clinical image?



- A. Prescribe oral corticosteroids
- B. Prescribe empirical oral antibiotics
- C. Discontinue antimicrobial bathing
- D. Discontinue topical corticosteroids

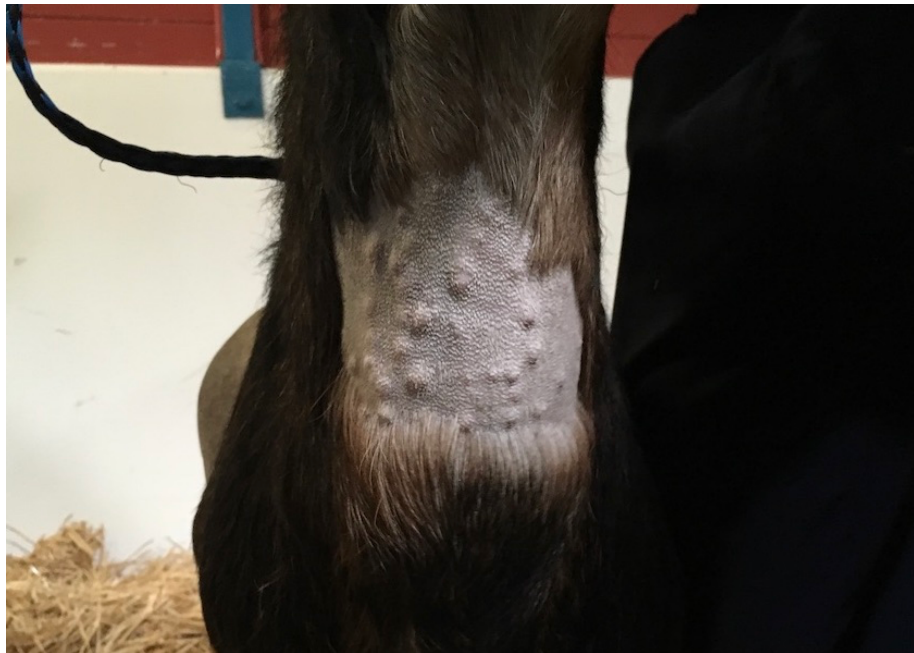**Question #13:**

Which keratin is predominately expressed by basal keratinocytes?

- A. K9
- B. K10
- C. K14
- D. K16

**Question #14:**

A fourteen-year-old sexually intact female Nubian goat is presented to a veterinarian for the skin lesions shown in the image below. The hair along the ventral neck is closely clipped to help visualize the skin lesions. Skin biopsies are collected and submitted for routine histology. The biopsy report describes “scattered hair follicles are markedly distended by hundreds of arthropods with a thin eosinophilic chitinous exoskeleton and short, jointed appendages”. Based on the clinical and histologic findings, what is the most likely etiologic agent for the depicted skin lesions?



- A. *Demodex caprae*
- B. *Draschia megastoma*
- C. *Przhevalskiana silenus*
- D. *Pelodera strongyloides*

**Question #15:**

A six-month-old castrated male German shorthaired pointer is presented to a veterinary dermatologist for diffuse scaling, alopecia, and pyrexia. The owner reports the dog experiences intermittent lameness and a “hunched” posture. What is the prognosis for the most likely disease process?

- A. Excellent – complete remission is expected with appropriate therapy
- B. Fair – response to therapy is good however dogs require chronic immunosuppression
- C. Guarded – response to therapy is often poor and complete remission is unlikely
- D. Grave – the disease progresses rapidly and is often fatal despite therapy